



ORIGINAL RESEARCH

Medicine Science 2017;6(4):653-8

Beneficial effects of melatonin on acetylsalicylic acid induced liver damage in rats

M. Ediz Sarihan¹, Hakan Parlakpınar², Alaattin Polat³, Nigar Vardi⁴, Onural Ozhan², Ahmet Acet²

¹ Inonu University, Faculty of Medicine, Department of Emergency Medicine, Malatya, Turkey

² Inonu University, Faculty of Medicine, Department of Pharmacology, Malatya, Turkey

³ Inonu University, Faculty of Medicine, Department of Physiology, Malatya, Turkey

⁴ Inonu University, Faculty of Medicine, Department of Embryology and Histology, Malatya, Turkey

Received 06 Apr 2017; Accepted 17 Apr 2017

Available online 10.05.2017 with doi: 10.5455/medscience.2017.06.8628

Abstract

We investigated the effects of acute high doses of acetylsalicylic acid (ASA) on liver tissue and the protective and therapeutic effects of melatonin on ASA related damage. Forty rats were randomly divided into five groups of eight: group 1, control; group 2, administered 200 mg/kg ASA; group 3, administered 5 mg/kg melatonin 45 min before ASA; group 4, administered 5 mg/kg melatonin 45 min after ASA; group 5, administered 5 mg/kg melatonin. We measured malondialdehyde (MDA), superoxide dismutase (SOD), catalase (CAT), glutathione peroxidase (GPx), reduced glutathione (GSH), myeloperoxidase (MPO) aspartate aminotransferase (AST) and alanine transaminase (ALT) in the liver. ASA treatment significantly increased MDA and MPO production, whereas it significantly decreased levels of SOD, CAT, GPx and GSH in the liver. Melatonin significantly decreased MDA and MPO production, whereas it caused increased levels of antioxidants. AST and ALT levels were higher after ASA treatment, whereas these levels were reduced significantly after melatonin administration. Our histopathological findings, including apoptosis, were consistent with the biochemical results. Melatonin exhibits beneficial effects against high dose ASA induced hepatotoxicity.

Keywords: Acetylsalicylic acid, liver, melatonin, oxidative stress, rat

Introduction

Acetylsalicylic acid (ASA) has been used as an analgesic, antipyretic and anti-inflammatory drug for many years [1]. ASA exerts these effects by inhibiting cyclo-oxygenase (COX), which blocks the pathway for prostaglandin synthesis from (arachidonic acid) [2,3]. ASA can block liver COX, which inhibits the synthesis of vasodilatory prostaglandins (PGs) in liver tissue and can cause deterioration of hepatic function [4]. ASA also increases oxidative stress, which causes toxicity and apoptosis [5-7].

The production of reactive oxygen species (ROS), depletion of cellular scavengers of ROS, arachidonic acid metabolism as a normal function, mitochondrial dysfunction and apoptosis have been reported to be the underlying causes for ASA induced hepatotoxicity [8]. Even low doses of ASA can cause lipid oxidation and impairment of defense mechanisms against oxidative injury [9,10]. The hepatotoxic side effects of ASA have been documented [11-13] One mechanism of this toxicity is believed to involve generation of ROS, which likely accounts for the pathophysiology of ASA induced hepatotoxicity. Free radicals can

attack DNA, membrane lipids and proteins. Free radical damage may be responsible for degenerative process but lipid oxidation plays much more important role in tissue damage [14].

The main secretory product of the pineal gland, melatonin (N-acetyl-5-methoxytryptamine), exhibits free radical scavenging and antioxidant properties, and reduces neutrophil accumulation [15]. Melatonin also indirectly activates antioxidative enzyme productions, reduces lipid oxidation and regulates gene expression of several protective enzymes such as Cu/Zn superoxide dismutase (CuZn SOD) and Mn superoxide dismutase [16-18]. In addition, the metabolites of melatonin are even more effective antioxidants than melatonin during oxidative stress and inflammatory pathways [19,20]. Melatonin limits the oxidative breakdown of lipids and reduces oxidative damage both in vivo and in vitro [14].

The toxic effects of high dose ASA taken during therapy, by accident or in suicide attempts have been documented [1,9,10,21]. Our literature review revealed no studies concerning the protective and therapeutic effects of melatonin against ASA induced hepatotoxicity. We also investigated the acute effects of high doses of ASA on liver tissue. To do this, we investigated histopathological changes in the liver and biochemical alterations including changes in liver malondialdehyde (MDA), superoxide dismutase (SOD), catalase (CAT), glutathione peroxidase (GPx), reduced glutathione (GSH), myeloperoxidase (MPO) aspartate aminotransferase (AST) and alanine transaminase (ALT) levels.

*Corresponding Author: M. Ediz Sarihan, Inonu University, Faculty of Medicine, Department of Emergency Medicine, Malatya, Turkey
E-mail: edizsarihan@hotmail.com

Material and Methods

Animals and experimental design

Our experimental design followed ARRIVE (Animal in Research: Reporting in Vivo Experiments) guidelines [22]. Our study was approved by the Animal Ethics Committee and was conducted in accordance with the Animal Welfare Act and Guide for the Care and Use of Laboratory animals, Animal Ethics Committee" (NIH publication No. 5377-3, 1996).

Forty healthy 250–300 g Wistar albino male rats five months aged were obtained from the Inonu University Laboratory Animals Research Center and housed in a temperature ($21 \pm 2^\circ \text{C}$) and humidity ($60 \pm 5\%$) controlled room with a 12 h light:12 h dark cycle. The rats were fed standard commercial pellets and water ad libitum.

The rats were divided randomly into five groups of eight: group 1, untreated controls; group 2, 200 mg/kg ASA injected intraperitoneally (i.p.); group 3, 5 mg/kg melatonin injected i.p. 45 min before i.p. injection of 200 mg/kg ASA; group 4, 5 mg/kg melatonin injected i.p. 45 min after injection i.p. of 200 mg/kg ASA, and group 5, 5 mg/kg melatonin injected i.p. All drugs were administered as a single dose. The dosage of ASA and melatonin were selected based on previous dose-response studies [4,23,24]. ASA and melatonin were purchased from Sigma Chemical Co. (St. Louis, MO).

Four hours after ASA treatment, all rats were sacrificed using an overdose of 70 mg/kg ketamine plus 8 mg/kg xylazine. Firstly, blood was collected via vena cava inferior for AST and ALT analysis. Then, the liver was removed and one half was placed in formaldehyde solution for routine histopathological examination by light microscopy; the remaining half was placed in liquid nitrogen and stored at -70°C until assayed for MDA, MPO, SOD, CAT, GPx and GSH.

Biochemistry

Liver samples were homogenized in ice-cold phosphate buffered saline, pH 7.4. The homogenate was sonified with an ultrasonifier (Bronson sonifier 450) using three cycles of 20 sec sonications and 40 sec pause on ice, then centrifuged at $15,000 \times g$ for 10 min at 4°C . Enzyme assays were performed immediately using the cell-free supernatant.

MDA content

MDA contents of the homogenates were assayed spectrophotometrically (UV-1601; Shimadzu, Kyoto, Japan) by measuring the presence of thiobarbituric acid reactive substances (TBARS) [19]. Three milliliters 1% phosphoric acid and 1 ml 0.6% thiobarbituric acid solution were added to 0.5 ml of plasma in a plastic tube. The mixture was heated in boiling water for 45 min. After the mixture cooled, the color was extracted into 4 ml n-butanol and the absorbance was measured at 532 nm. The amount of lipid peroxide was calculated as TBARS of lipid oxidation. The results were expressed as nmol/g tissue.

SOD activity

Total (Cu-Zn and Mn) SOD activity was assayed using the method of Sun et al. (2004). The method is based on the inhibition of nitroblue tetrazolium (NBT) reduction by the xanthine-xanthine

oxidase system as a superoxide generator. SOD activity was expressed as U/g protein.

CAT activity

CAT activity was assayed using the method described by Aebi (1984). The assay is based on the determination of catalytic or peroxide activity of CAT. Results were expressed as K/g protein.

GPx activity

GPx activity was measured using the method described by Paglia and Valentine (1967). An enzymatic reaction in a glass plastic tube containing NADPH, GSH, sodium azide and glutathione reductase was initiated by adding H₂O₂ and the change in absorbance at 340 nm was monitored using a spectrophotometer. Results were expressed as U/g protein.

GSH content

GSH content was measured as nonprotein sulfhydryls in the liver tissue using the described method described by Uzbay et al. (2013). Aliquots of tissue homogenate were mixed with distilled water and 50% trichloroacetic acid in glass tubes and centrifuged at 3000 rpm for 15 min. The supernatants were mixed with 0.4 M Tris buffer, pH 8.9, and 0.01 M 5,5'-dithiobis (2-nitrobenzoic acid (DTNB) was added. After shaking the reaction mixture, the absorbance was measured against a blank with no homogenate at 412 nm within 5 min of the addition of DTNB. The absorbance values were extrapolated from a glutathione standard curve and expressed as $\mu\text{mol/g}$ tissue.

MPO activity

MPO activity was determined using a 4-aminoantipyrine/phenol solution as the substrate for MPO-mediated oxidation by H₂O₂ and the change in absorbance at 510 nm was recorded [25]. One unit of MPO activity was defined as the amount that caused degradation of 1 μmol H₂O₂/min at 25°C . The results were expressed as U/g protein.

ALT and AST concentrations

We measured the plasma concentrations of the liver enzymes, ALT and AST, in serum samples of all groups of rats. The blood samples were centrifuged quickly to evaluate the serum levels of AST and ALT using an Olympus Autoanalyzer (Olympus Instruments, Tokyo, Japan). Activities were expressed as IU/L.

Histology

Liver tissue was fixed in 10% formalin and embedded in paraffin. The sections were stained with hematoxylin and eosin (H & E) and periodic acid-Schiff (PAS), and examined by observers blinded to the identities of the sections. We used the following criteria for liver damage: sinusoidal dilation, congestion, intracytoplasmic vacuolization and necrotic changes including nuclear pyknosis or lysis, cytoplasmic alterations including absent cell boundaries, eosinophilia and cytoplasmic retraction. The degree of cellular alteration was scored semi-quantitatively as: 0, absent; 1, slight; 2, moderate; and 3, severe for each criterion. The overall tissue score was calculated as the sum of the scores for each criterion.

Immunohistochemistry

Five μm thick sections were mounted on polylysine coated slides for immunohistochemical analysis. A section of tonsil was used as positive control. After rehydrating through a graded series of

alcohols, the samples were transferred to citrate buffer, pH 7.6, and heated in a microwave oven for 20 min. After cooling for 20 min at room temperature, the sections were washed with phosphate-buffered saline (PBS). The sections were placed in 0.3% H₂O₂ for 7 min, then washed with PBS. The sections were incubated with primary rabbit-polyclonal cysteine aspartate specific proteinase (caspase-3) (Neomarker, California) antibody for 30 min. The caspase-3 kit was used according to the manufacturer's instructions with minor timing exceptions, then rinsed in PBS and incubated with biotinylated goat anti-polyvalent for 10 min and streptavidin peroxidase for 10 min at room temperature. Staining was completed with chromogen + substrate for 15 min, counterstained with Mayer's hematoxylin for one min, rinsed in tap water and dehydrated. The sections were examined using a Leica DFC 280 light microscope (Leica Micros Imaging Solution Ltd., Cambridge, UK) by a histopathologist who was blinded to the origin of the sections. Caspase-3 positive cells were stained brown. Hepatocytes stained with caspase-3 were evaluated using Leica Q Win Image Analysis System. Caspase-3 stained cells were graded as: 0, none or a few stained hepatocytes; 1, stained hepatocytes < 25% of the sample; 2, stained hepatocytes 25–50% of the sample; 3, stained hepatocytes 50–75% of the sample; 4, stained hepatocytes > 75% of the sample. Ten microscopic fields were analyzed using a 20 x objective for each specimen.

Statistical analysis

The sample sizes required for a power of 0.80 were estimated using

NCSS software. All data were analyzed using a commercially available statistical software package (SPSS for Windows v. 22.0, Chicago, IL). Distributions of the groups were analyzed using the Kolmogorov-Smirnov test. Because all groups showed a normal distribution except for the number of hepatocytes stained with caspase-3, parametric statistical methods were used. After a significant Kruskal–Wallis H test, a Conover test also was performed for the histopathological results (Table 3). These histopathological results are given as medians (min–max). For other parameters, One-way ANOVA was performed with Tukey's post-hoc test. Biochemical data are reported as means \pm SD. Values for $p \leq 0.05$ were considered statistically significant.

Results

All animals survived the experiment. There were no significant differences in the liver weights among the groups (data not shown).

Biochemistry

Effects of melatonin on serum parameters

The serum levels of AST and ALT were increased in rats given ASA compared to controls (132.17 ± 4.5 vs. 64.24 ± 2.1 and 102.05 ± 6.4 vs. 27.19 ± 2.4 U/L, respectively (Table 1). AST and ALT levels were significantly decreased in the melatonin treated groups 3 and 4 compared to controls (70.34 ± 4.3 vs. 68.13 ± 2.8 and 35.29 ± 4.4 vs. 30.13 ± 5.8 , respectively).

Table 1. Effects of melatonin on biochemical parameters

Groups	MDA	CAT	GPx	GSH	MPO	SOD	AST	ALT
	(nmol/g tissue)	(K/g protein)	(U/g protein)	(μ /g tissue)	(U/g protein)	(U/g protein)	IU/L	IU/L
	Mean \pm SD	Mean \pm SD	Mean \pm SD	Mean \pm SD	Mean \pm SD	Mean \pm SD	Mean \pm SD	Mean \pm SD
Control	48.9 \pm 14.9	38.3 \pm 4.4	4.7 \pm 1.3	2.6 \pm 0.4	15.2 \pm 4.7	34.3 \pm 7.1	64.2 \pm 2.1	27.2 \pm 2.4
ASA	70.2 \pm 12.6a	18.2 \pm 3.36a	2.2 \pm 0.5a	1.7 \pm 0.3a	27.3 \pm 6.2a	22.1 \pm 5.2a	132.2 \pm 4.5a	102.1 \pm 6.4a
MEL + ASA	47.5 \pm 12.9b	26.2 \pm 4.9b	4.6 \pm 0.4b	2.4 \pm 0.4b	18.2 \pm 3.4b	32.3 \pm 7.3b	75.1 \pm 3.2b	31.5 \pm 3.8b
ASA + MEL	33.8 \pm 5.5b	27.1 \pm 3.0b	4.5 \pm 0.4b	2.4 \pm 0.4b	15.5 \pm 3.3b	31.8 \pm 2.5b	70.3 \pm 4.3b	35.3 \pm 4.4b
MEL	39.6 \pm 14.3b	36.9 \pm 6.9b	4.8 \pm 1.1b	2.3 \pm 0.5b	14.7 \pm 1.5b	37.3 \pm 6.8b	68.1 \pm 2.8b	30.1 \pm 5.8b

MEL, melatonin; ASA, acetylsalicylic acid; AST, aspartate aminotransferase; ALT, alanine aminotransferase. ap < 0.05 vs. control group; bp < 0.05 vs. ASA group.

Effects of melatonin on antioxidant and oxidative stress status

Our findings are presented in Table 1. Briefly, production of both MDA and MPO in liver tissue was significantly greater than in controls in the ASA group, whereas SOD and CAT activities were significantly less than in the control group. Melatonin treatment both reduced the levels of MDA and MPO, and elevated SOD and CAT enzyme activities, significantly. Also, compared to the control group, ASA treatment caused significant reduction of both GPx and GSH levels in the liver tissue. Melatonin treatment significantly elevated GPx activity.

Histopathological analysis

Hepatocytes and sinusoids appeared normal in the control and melatonin groups, (Fig. 1A, B). PAS staining appeared where Kupffer cells were present (Fig. 1C, D). In the ASA group, the radial arrangement of hepatocytes from central vein toward the

periphery was deformed. Separated irregular areas consisting of necrotic hepatocytes were observed in the centrilobular region (Fig. 2A). In addition, vacuolization and increased eosinophilia was observed in the cytoplasm of some cells scattered randomly within areas with normal morphology (Fig. 2B). Eosinophilic cells, and shrinkage and darkened nuclei were increased in ASA group compared to controls. Fragmented hepatocytes were observed frequently around the central vein. Other conspicuous findings in ASA-treated group included sinusoidal dilation and congestion (Fig. 2C), and an increased number of Kupffer cell in this group compared to controls (8.1 ± 0.38) (Fig. 2D).

The architecture of the hepatocytes was altered less in the melatonin + ASA (group 3) and ASA + melatonin (group 4) groups, than in the ASA group. Most of the nuclei were euchromatic and shaped normally. Melatonin treatment did not ameliorate structural

alterations completely, however. The mild degenerative alterations such as sinusoidal dilatation were observed (Fig. 3A, B).

Cytoplasmic vacuolization and congestion were more prominent in the ASA + melatonin group (group 4) than in the melatonin + ASA group (group 3) (Fig. 3C, D). In both groups 3 and 4, melatonin treatment reduced the number of Kupffer cells significantly (Fig. 4A, B). The semiquantitative histological analysis and the number of Kupffer cell in the liver tissue are given in Table 2.

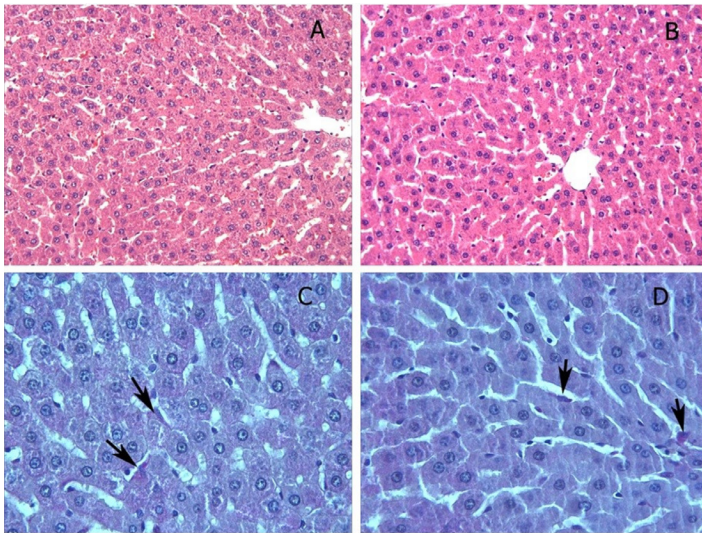


Figure 1. Control (A, C) and MEL groups (B, D); The normal hepatocytes architecture and the central vein. Hepatocytes cords radiate from the central vein to the periphery of the lobule as the sinusoids, H-E X66. (C) and (D) Appearance of PAS-positive stained Kupffer cells (arrows) within sinusoidal lumen, PAS X132.

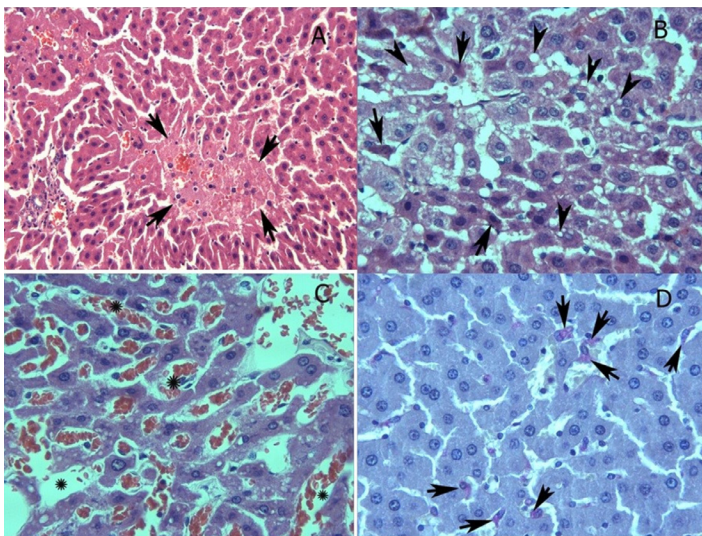


Figure 2. ASA group (A); Distruption of radial arrangement of hepatocytes is visible. Irregular area is comprised of hepatocytes with cell boundaries lost (arrows), H-E X66 (B) Hepatocytes with dense eosinophilic cytoplasm (arrows) and multiple intracytoplasmic vacuoles (arrow heads) are seen in centrilobular area, H-E X132. (C) Another striking finding is the presence of sinusoidal dilatation and congestion (stars), H-E X132. (D) An increase in the number of Kupffer cells is observed than control group (arrows), PAS X132.

We found no caspase-3 immunostaining of the hepatocytes except

for a few apoptotic cells in the control and melatonin groups (not shown). To the contrary, we observed that caspase-3 positive cells were increased significantly in the ASA group compared to controls (Fig. 5A). In group 4, melatonin treatment reduced the number of apoptotic cells significantly (Fig. 5B); however, prior to ASA treatment, melatonin did not prevent apoptosis immunoreactivity induced by ASA (Fig. 5C). The results of caspase-3 staining are given in Table 3.

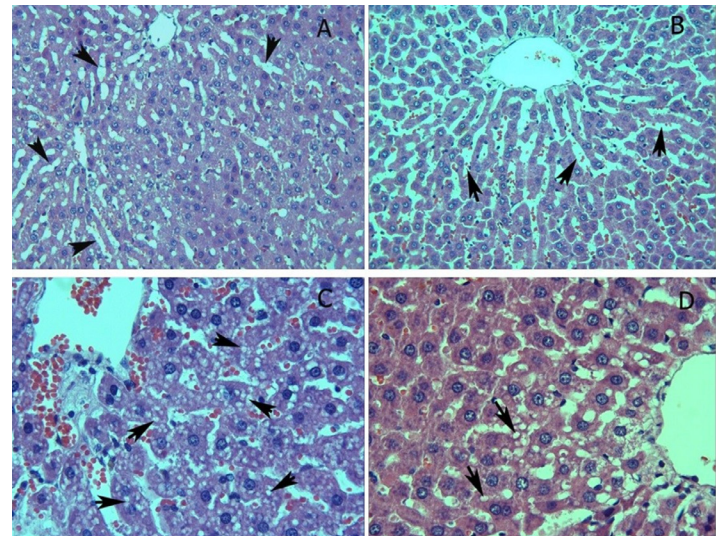


Figure 3. ASA+melatonin (A) and Melatonin+ASA groups (B); Although the the radial arrangement of hepatocytes is observed as relatively regular as moderate degenerative changes such as sinusoidal dilatation is still present in some area in both of groups (arrows), H-E X66. ASA+melatonin group (C); Intracytoplasmic vacuolisation (arrows) is evident (arrows), H-E X132. Melatonin+ASA group (D); Reduction in intracytoplasmic vacuolisation is observed according to ASA+melatonin group (arrows), H-E X132

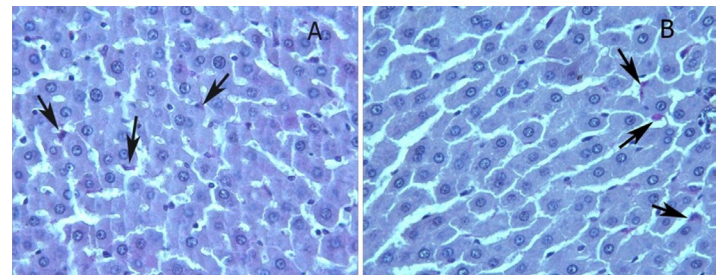


Figure 4. ASA+melatonin (A) and Melatonin+ASA groups (B); Reduction in the number of Kupffer cells is seen in melatonin treatment groups according to ASA group (arrows), PAS X132.

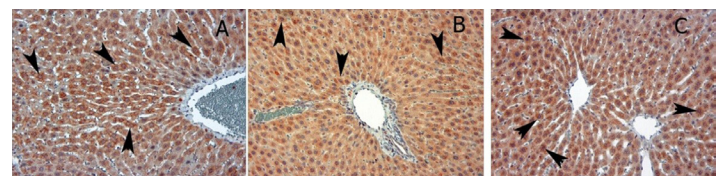


Figure 5. ASA group (A); marked caspase-3 staining is seen in the hepatocytes (arrows), ASA+melatonin group (B); there is a prominent reduction caspase-3 staining in hepatocytes according to ASA (arrows), Melatonin+ASA group (C); view of caspase-3 staining is similar to ASA+melatonin group (arrows), X

Table 2. Histological damage score and number of Kupffer Cells

Groups	Congestion	Sinusoidal dilation	Vacuolization	Necrosis	Kupffer cells
1. Control	0.1 ± 0.0	0.3 ± 0.2	0.2 ± 0.1	0.0 ± 0.0	4.1 ± 0.35
2. MEL	0.0 ± 0.0	0.1 ± 0.1	0.2 ± 0.1	0.0 ± 0.0	4.4 ± 0.28
3. ASA	1.2 ± 0.2	1.9 ± 0.2	0.7 ± 0.2	1.2 ± 0.2	8.1 ± 0.38
4. MEL + ASA	0.6 ± 0.2	1.0 ± 0.2	1.1 ± 0.4	0.4 ± 0.2	5.9 ± 0.40
5. ASA + MEL	0.2 ± 0.1	1.3 ± 0.2	0.2 ± 0.1	0.7 ± 0.3	5.7 ± 0.28
	p < 0.0001	p < 0.0001	p = 0.0248	p = 0.0001	p < 0.0001
	1) 3,4	1) 3,4, 5	1) 4	1) 3, 5	1) 3,4, 5
	2) 3, 4	2) 3, 4, 5	2) 4	2) 3, 5	2) 3, 4, 5
	3) 1, 2, 4, 5	3) 1, 2, 4	3)	3) 1, 2, 4,5	3) 1, 2, 4, 5
	4) 1, 2, 3	4) 1, 2, 3	4) 1, 2, 5	4) 3	4) 1, 2, 3
	5) 3	5) 1, 2	5) 4	5) 1, 2, 3	5) 1, 2, 3

MEL, melatonin; ASA, acetylsalicylic acid.

Table 3. Number of hepatocytes stained for caspase-3

Groups	Median (min-max)	p < 0.0001
Control	0.5 (0.0 - 2.0)	3, 4, 5
MEL	0.0 (0.0 - 2.0)	3, 4, 5
ASA	3.0 (1.0 - 4.0)	1, 2, 4
ASA + MEL	2.0 (1.0 - 3.0)	1, 2, 3, 5
MEL + ASA	3.0 (1.0 - 4.0)	1, 2, 4

MEL, melatonin; ASA, acetylsalicylic acid.

Discussion

We found that ASA treatment caused impairment of the antioxidant system in rat liver and that the deleterious effects of ASA could be detected by biochemical analysis and histopathology. Melatonin exhibited a preventive effect against the deleterious effects of ASA.

ROS possess a highly reactive unpaired electron that attacks biomolecules. The innate antioxidant system defends against oxidative stress. Deterioration of the balance between the rate of formation of ROS and antioxidant defenses causes cell injury by damaging membranes, DNA, protease activation, and lipid and protein oxidation, which culminate in apoptotic and necrotic cell death [26].

Viral infections, drug or alcohol toxicity, ischemia-reperfusion and drug induced hepatotoxicity among other factors can damage hepatocytes by causing oxidative stress and inflammation [23,27]. ASA is a commonly used drug and even at therapeutic doses can cause increased ROS and oxidative injury as evidenced by decreased levels of GPx, GSH and SOD, which together cause mitochondrial dysfunction [28,29].

We found that ASA caused increased production of MDA, which indicates the effects of oxidative stress on lipids, and MPO, which indicates inflammation owing to lipid oxidation. MPO participates in the generation of oxidants by neutrophils. ASA increases MDA levels even at low, otherwise nontoxic doses [10]. D'Argenio et al. [30] reported that ASA doubled gastric MDA production. MDA is a good indicator of the rate of lipid oxidation reported that minimal lipid oxidation levels in rat liver tissue are at 01:00 h, simultaneous with the peak time of melatonin synthesis [31,32]. GSH is an

antioxidant that prevents ROS damage to cellular components. Consistent with above-mentioned biochemical these results, we reported earlier that administration of melatonin increased GSH levels significantly and reduced MDA production in the liver tissue of pinealectomized (PX) rats [14].

We found that administering melatonin before and after ASA treatment decreased MDA and MPO production compared to rats treated only with ASA. ASA treatment also decreased the levels of SOD, CAT, GPx and GSH significantly in the liver tissue. We found that melatonin ameliorated the content of these antioxidants to near normal levels. Our observations are consistent with earlier studies of melatonin effects on antioxidants [33-37]. We investigated earlier the protective and therapeutic effects of melatonin treatment against ASA induced kidney and testis damage [38]. We found that ASA increased MDA levels in both kidney and testis significantly, whereas it decreased the levels of SOD, CAT, GPx and GSH significantly in the kidney and CAT levels in testis. Melatonin significantly decreased MDA levels in the kidney and ameliorated the levels in the testis, whereas it elevated the levels of antioxidants.

Hepatotoxicity can be determined readily by liver function tests [39]. In the current study, we showed that melatonin treated group ameliorated the histological damage significantly. Our biochemical analyses and histopathological observations were consistent with each other.

We demonstrated the beneficial effect of melatonin on high-dose ASA induced liver injury. We found that ASA is a powerful oxidizing agent that caused significant oxidative damage to the rat liver tissue. According to our biochemical and histopathological results, melatonin exhibited protective effects against ASA induced hepatotoxicity by its antioxidant and free radical scavenging effects in rats. We believe that the antioxidant properties of melatonin could protect against the toxic effects of ASA on liver tissue and that it could be used to prevent liver injury caused by the use of high doses of ASA. Further experimental and clinical studies are required to confirm our findings before conducting clinical applications for treating ASA induced hepatotoxicity.

Declaration of interest: The authors report no conflicts of interest. The authors alone are responsible for the content and writing of this paper.

References

1. Voelker M, Hammer M. Dissolution and pharmacokinetics of a novel micronized aspirin formulation. *Inflammo pharmacology*. 2012;20(4):225-31.
2. Hersh EV, Moore PA, Ross GL. Over-the-counter analgesics and antipyretics: a critical assessment. *Clin Ther*. 2000;22(5):500-48.
3. Schrör K. 100 years of successful drug discovery. The history of aspirin. *Pharm Unserer Zeit*. 2009;38(4):306-13.
4. Gaspari F, Perico N, Locatelli M, Corna D, Remuzzi G, Garattini S. Renal handling of aspirin in the rat. *J Pharmacol Exp Ther*. 1989;251(1):295-304.
5. Al-Nasser IA. Salicylate-induced kidney mitochondrial permeability transition is prevented by cyclosporin A. *Toxicol Lett*. 1999;105(1):1-8.
6. Goel A, Chang DK, Ricciardiello L, Gasche C, Boland CR. A novel mechanism for aspirin-mediated growth inhibition of human colon cancer cells. *Clin Cancer Res*. 2003;9(1):383-90.
7. Dikshit P, Chatterjee M, Goswami A, Mishra A, Jana NR. Aspirin induces apoptosis through the inhibition of proteasome function. *J Biol Chem*. 2006;281(39):29228-35.
8. Nadanaciva S, Aleo MD, Strock CJ, Stedman DB, Wang H, Will Y. Toxicity assessments of nonsteroidal anti-inflammatory drugs in isolated mitochondria, rat hepatocytes, and zebrafish show good concordance across chemical classes. *Toxicol Appl Pharmacol*. 2013;272(2):272-80.
9. Durak I, Karaayvaz M, Cimen MY. Aspirin impairs antioxidant system and causes peroxidation in human erythrocytes and guinea pig myocardial tissue. *Hum Exp Toxicol*. 2001;20(1):34-7.
10. Kesik V, Lenk MK, Kurekci AE. Do zinc and selenium prevent the antioxidant, hepatic and renal system impairment caused by aspirin in rats? *Biol Trace Elem Res*. 2008;123(1-3):168-78.
11. Nakagawa M, Ishihara N, Shimokawa T, Kojima S. Effect of colifibrate on lipid peroxidation in rats treated with aspirin and 4-pentenoic acid. *J Biochem*. 1987;101(1):81-8.
12. Aebi HE. Catalase in vitro. *Methods Enzymol*. 1984;105:121-6.
13. Zhang X, Ouyang J, Thung SN. Histopathologic manifestations of drug-induced hepatotoxicity. *Clin Liver Dis*. 2013;17(4):547-64.
14. Sahna E, Parlakpınar H, Vardi N, Cigremis Y, Acet A. Efficacy of melatonin as protectant against oxidative stress and structural changes in liver tissue in pinealectomized rats. *Acta Histochem*. 2004;106(5):331-6.
15. Parlakpınar H, Acet A, Gul M, Altinoz E, Esrefoglu M, Colak C. Protective effects of melatonin on renal failure in pinealectomized rats. *Int. J. Urol*. (2007);14: 743-748.
16. Watson RR. Melatonin in the promotion of health, 2nd edition. CRC Press, Florida. 2012;355.
17. Mizrak B, Parlakpınar H, Acet A, Turkoz Y. Effects of pinealectomy and exogenous melatonin on rat hearts. *Acta Histochem*. 2004;106(1):29-36.
18. Fadillioglu E, Kurcer Z, Parlakpınar H, Iraz M, Gursul C. Melatonin treatment against remote organ injury induced by renal ischemia reperfusion injury in diabetes mellitus. *Arch Pharm Res*. 2008;31(6):705-12.
19. Silva SO, Rodrigues MR, Carvalho SR, Catalani LH, Campa A, Ximenes VF. Oxidation of melatonin and its catabolites, N1-acetyl-N2-formyl-5-methoxykynuramine, N1-acetyl-5-methoxykynuramine, by activated leukocytes. *J Pineal Res*. 2004;37(3):171-5.
20. Onuki J, Almedia EA, Medeiros MH, Di Mascio P. Inhibition of 5-aminolevulinic acid-induced DNA damage by melatonin, N1-acetyl-N2-formyl-5-methoxykynuramine, quercetin or resveratrol. *J Pineal Res*. 2005;38(2):107-15.
21. Didolkar AK, Patel PB, Roychowdhury D. Effect of aspirin on spermatogenesis in mature and immature rats. *Int J Androl*. 1980;3(5):585-93.
22. Colak C, Parlakpınar H. Hayvan Deneyleri: in vivo denemelerin bildirimi: ARRIVE kılavuzu-Derleme. *J Turg Ozal Med Cent*. 2012;19(2):128-31.
23. Livio M, Benigni A, Zoja C. Differential inhibition by aspirin of platelet thromboxane and renal prostaglandins in the rat. *J Pharmacol Exp Ther*. 1989;248(1):334-41.
24. Uzbay T, Parlakpınar H, Akdag E, Celik T, Yasarbas G, Ulusoy G, Acet A, Kose A, Kayir H. Chronic melatonin treatment reverses disruption of prepulse inhibition in pinealectomized and pinealectomized-plus-ovariectomized rats. *Behav Brain Res*. 2013;239:1-7.
25. Wei H, Frenkel K. Relationship of oxidative events and DNA oxidation in Sencar mice to in vivo promoting activity of phorbol ester-type tumor promoters. *Carcinogenesis*. 1993;14(6):1195-201.
26. Parlakpınar H, Orum MH. The antioxidant effect of melatonin on myocardial ischemia reperfusion injury in experimental studies. *Med Science*. 2014;3(4):1766-80.
27. Colak C, Parlakpınar H, Ozer MK, Sahna E, Cigremis Y, Acet A. Investigating the protective effect of melatonin on liver injury related to myocardial ischemia-reperfusion. *Med Sci Monit*. 2007;13(11):BR251-254.
28. Lien YH, Lai LW, Silva AL. Pathogenesis of renal ischemia/reperfusion injury: lessons from knockout mice. *Life Sci*. 2003;74(5):543-52.
29. Raza H, John A, Benedict S. Acetylsalicylic acid-induced oxidative stress, cell cycle arrest, apoptosis and mitochondrial dysfunction in human hepatoma HepG2 cells. *Eur J Pharmacol*. 2011;668(1-2):15-24.
30. D'Argenio G, Mazzone G, Tuccillo C. Apple polyphenol extracts prevent aspirin-induced damage to the rat gastric mucosa. *Br J Nutr*. 2008;100(6):1228-36.
31. Belanger PM, Desgagne M, Bruguierolle B. Temporal variations in microsomal lipid peroxidation and in glutathione concentration of rat liver. *Drug Metab Disp*. 1991; 19(1):241-244.
32. Parlakpınar H, Orum MH, Sagir M. Pathophysiology of myocardial ischemia reperfusion injury: a review. *Med. Science*. 2013;2(4):935-54.
33. Reiter RJ, Tan DX, Maldonado MD. Melatonin as an antioxidant: physiology versus pharmacology. *J Pineal Res*. 2005;39(2):215-6.
34. Rodriguez C, Mayo JC, Sainz RM. Regulation of antioxidant enzymes: a significant role for melatonin. *J Pineal Res*. 2004;36(1):1-9.
35. Winiarska K, Fraczyk T, Malinska D, Drozak J, Bryla J. Melatonin attenuates diabetes induced oxidative stress in rabbits. *J Pineal Res*. 2006;40(2):168-176.
36. Hardeland R, Pandi-Perumal SR, Cardinali DP. Melatonin. *Int J Biochem Cell Biol*. 2006;38(3):313-6.
37. Gurlek A, Celik M, Parlakpınar H, Aydogan H, Bay-Karabulut A. The protective effect of melatonin on ischemia-reperfusion (I/R) injury in the groin (inferior epigastric) flap model in rats. *J Pineal Res*. 2006;40(4):312-7.
38. Altintas R, Polat A, Parlakpınar H, Vardi N, Beytur A, Oguz F, Sagir M, Yildiz A, Duran ZR. The effect of melatonin on acetylsalicylic acid-induced kidney and testis damage. *Hum Exp Toxicol*. 2014;33(4):383-95.
39. Sun Y, Yang J, Wang LZ, Sun LR, Dong Q. Crocin attenuates cisplatin-induced liver injury in the mice. *Hum Exp Toxicol*. 2014;33(8):855-62.